

K. N. Fountas · E. Kapsalaki · M. Kassam ·  
C. H. Feltes · V. G. Dimopoulos · J. S. Robinson ·  
J. R. Smith

## Management of intracranial meningeal hemangiopericytomas: outcome and experience

Received: 11 January 2005 / Revised: 29 March 2005 / Accepted: 28 August 2005  
© Springer-Verlag 2005

**Abstract** Hemangiopericytomas represent rare intracranial tumors that have a tendency to recur locally and have the unique characteristic of giving extracranial metastases. Our current communication reviews a series of patients diagnosed with hemangiopericytoma who were treated in our facility. Eleven patients with a mean age of 51.2 years underwent follow-up for a mean time of 7.1 years. Their neuroimaging preoperative evaluation included plain skull X-rays, head CT scans, brain MRI, angiograms, and <sup>1</sup>HMRS. Preoperative embolization of the tumor was employed in 6/11 patients. All patients underwent craniotomy for tumor resection and postoperative radiation treatment was employed on all but one. Grade I resection was accomplished in 6/11 (54.5%), grade III in 4/11 (36.4%), and grade IV in 1/11 (9.1%). Local recurrence was detected in 3/11 (27.3%) at a mean period of 5 (range 2–7.5) years. Extracranial metastatic disease was documented in 4/11 (36.4%) patients at a mean of 4.9 (range 2.5–7) years after the initial diagnosis. The GOS score was: 7/11 (63.6%) scored 5, while 4/11 (36.4%) died at a mean time of 5.5 (range 3–8) years after the initial diagnosis. Intracranial hemangiopericytomas management requires aggressive surgical resection, postoperative radiation treatment, and extensive follow-up to rule out local recurrences and delayed extracranial metastases.

**Keywords** Embolization · Hemangiopericytoma · Intracranial · Metastasis · MR spectroscopy · Recurrence · Surgical outcome

### Introduction

Intracranial meningeal hemangiopericytomas represent very rare tumors of mesenchymal origin [10, 14, 35, 45]. These intracranial, extra-axial tumors constitute approximately 1% of all intracranial tumors and are histologically identical to the peripheral hemangiopericytomas [14, 35, 69, 84]. It is widely accepted that these tumors originate from Zimmerman's pericytes, which are leiomyoblastic cells spiraling around capillaries and postcapillary venules [15, 61, 69]. These cells were first described in 1923 [20] and later on their association to hemangiopericytomas was established [14, 15, 61, 69].

The first description of an extracranial hemangiopericytoma was made by Stout and Murray in 1942 [81], while Begg and Garret [9] were the first ones to report a primary intracranial meningeal hemangiopericytoma in 1954. It needs to be noted, though, that in 1928 Bailey et al. described a hemangiopericytoma as a lesion which was thought to be an angioblastic subtype of meningioma [6]; later on, Cushing and Eisenhardt described a similar lesion and classified it as a variant of a meningioma, originating from meningoendothelial cells with angioblastic characteristics [24]. These initial reports were only the beginning of a long-standing controversy regarding the histological classification, origin, and nomenclature of these tumors [9, 29, 48, 53, 61, 69, 71]. This controversy is well reflected in the use of the similar, but conceptually opposite terms, "hemangiopericytic meningioma" and "meningeal hemangiopericytoma" for describing these lesions [15]. Horten et al. [40], argued that these tumors originate from multipotential precursor cells and should be classified as meningiomas, while Popoff et al. [71] advocated for not classifying them as meningiomas, since these tumors were histologically identical to hemangiopericytomas of peripheral soft tissues. Although the intracranial hemangioperi-

K. N. Fountas (✉) · E. Kapsalaki · M. Kassam · C. H. Feltes ·  
V. G. Dimopoulos · J. S. Robinson  
Department of Neurosurgery,  
Medical Center of Central Georgia,  
Mercer University, School of Medicine,  
Macon, GA 31201-2155, USA  
e-mail: knfountasmd@excite.com  
Tel.: +1-478-7437092  
Fax: +1-478-7430523

J. R. Smith  
Department of Neurosurgery,  
Medical College of Georgia,  
Augusta, GA 30912, USA

cytomas share macroscopic and imaging characteristics with meningiomas, their more aggressive behavior, their tendency for early recurrence and extracranial metastasis as well as their worst prognosis has been recognized [4, 13, 15, 26, 27, 34, 45, 84–86]. Finally, in 1993, the World Health Organization separated hemangiopericytomas from meningiomas and classified them as a separate histopathological entity [27].

The rarity of these tumors, along with their controversial histologic classification, makes their misdiagnosis quite frequent and their treatment quite challenging. The existence of very limited clinical series and the aggressive behavior of these lesions, make the understanding of their histologic profile and the factors influencing their outcome mandatory. In our current communication, we report our data and our observations from treating 11 patients in our department diagnosed with intracranial hemangiopericytoma.

## Materials and method

In our institution, 14 patients had been diagnosed with intracranial hemangiopericytoma over a period of 10 years (1993–2003). Unfortunately, we lost track of three of these patients during their follow-up and, therefore, they were excluded from this study; the other eleven patients (seven males and four females), with mean age of  $51.2 \pm 0.2$  years at the time of diagnosis (age range 20–68 years), remained in the study (Table 1).

The preoperative imaging studies of these patients included plain skull X-rays in 4/11 (36.4%) patients, head CT scans±contrast in 11/11 (100%) patients, angiograms in 9/11 (81.8%), and brain MRI±Gd-DTPA in 8/11 (72.7%). All the studies included T1- and T2-weighted images (WI) and postcontrast T<sub>1</sub>WI, while in three patients, FLAIR pulse sequence images were also obtained. Single-voxel ( $1 \times 1 \times 1$  cm)<sup>1</sup>H MRS, single spin echo with TR/TE—1,600/135 ms, PRESS and CHESS RF pulse sequences for water-signal suppression (1.5 T unit, Magnetom 63/84 SP, Siemens, Erlangen, Germany)—was also obtained in 4/11 (36.4%) patients.

All these patients underwent craniotomy for resection of their newly diagnosed tumors, while two patients underwent a total of three craniotomies for recurrent tumor resection. The extent of resection was quantitated via Simpson's scale [80]. All craniotomies were performed under general endotracheal anesthesia. In 6/11 (54.5%) of these patients, a preoperative embolization was employed for minimizing operative blood loss. The removed tumors were separately examined (gross, microscopic, immunohistochemical examination, and electron microscopy) independently by two experienced neuropathologists. The resected tissue specimens were fixed in 10% formaldehyde, embedded in paraffin and stained for histologic examination with Gomori, PAS, HE, Alcian blue, and van Gieson's picrofuchsin stains, and were thoroughly examined via light microscopy. Immunostaining was performed on paraffin sections with anti-Cytokeratin, anti-CD 34, anti-Desmin, anti-epithelial membrane antigen, anti-fibronectin, anti-Factor

**Table 1** Demographics, treatment, and outcome data of our patients

Patient	Age	Sex	Tumor location	Degree of resection (Simpson scale)	Follow-up (years)	Metastases	Local recurrence	Glasgow outcome scale score
M.W.	68	M	L sphenoid wing	III	11	None	None	5
G.D.	43	M	L parasagittal	III	8	Lung after 7 years	Recurrence after 7.5 years	1
R.T.	59	M	M R temporal fossa	I	10	None	None	5
S.F.	58	F	F R sphenoid wing	IV	3	Liver after 2.5 years	Recurrence after 2 years	1
P.O.	48	M	R convexity	I	9	None	None	5
S.T.	67	M	R sphenoid wing	III	4	Bone after 3.5 years	None	1
F.G.	59	F	L parasagittal	III	7	Lung after 6.5 years	Recurrence after 5.5 years	1
H.G.	37	F	R parasagittal	I	8	None	None	5
R.R.	20	M	R parasagittal	I	5	None	None	5
W.B.	49	M	L convexity	I	4	None	None	5
P.R.	55	F	R parasagittal	I	9	None	None	5

XIIIa, anti-Factor VIII R Ag, anti-gial fibrillary acid protein, anti-S-100 protein, anti-type IV collagen, anti-Vimentin, and anti-Ulex europaeus lectin. Finally, the tissue specimens for electron microscopy were fixed with paraformaldehyde-glutaraldehyde and postfixed with osmium tetroxide. The fixed specimens were thoroughly dehydrated in a graded series of ethanol and finally embedded in Epon 812. Ultra-thin sections were stained with uranyl acetate and lead citrate. The diagnosis of hemangiopericytomas was established in all these cases.

In 10/11 (90.9%) of our patients, postoperative external radiation therapy was employed, while one patient refused any further treatment. The administered dosages ranged between 50–60 Gy while the mean dose was 58.6 Gy. Their follow-up time ranged between 3 and 11 years (mean follow-up time  $7.1 \pm 0.1$  years). Their follow-up evaluation included thorough clinical examinations, brain MRI for the ruling out of any local recurrences, and appropriate imaging and laboratory studies in cases of suspected systemic metastatic disease.

---

## Results

All of the tumors in our series were supratentorial; more specifically, five were parasagittal (in two of these cases there was invasion of the superior sagittal sinus), three originated from the medial third of the sphenoid wing (in one of these cases there was extension of the tumor into the ipsilateral orbit), two were convexity lesions, and one lesion was located in the temporal fossa.

The most common presenting symptom in our series was headache in 8/11 (72.7%) patients. In the remaining patients, symptomatology was related to tumor location rather than intracranial hypertension. One patient presented with lower extremity motor deficit, while another patient with exophthalmos; finally, one patient presented with a single syncopal episode. Characteristically, none of our patients experienced any seizures. The average duration of symptoms in our series was 17.6 weeks, while the range was between 2 and 32 weeks.

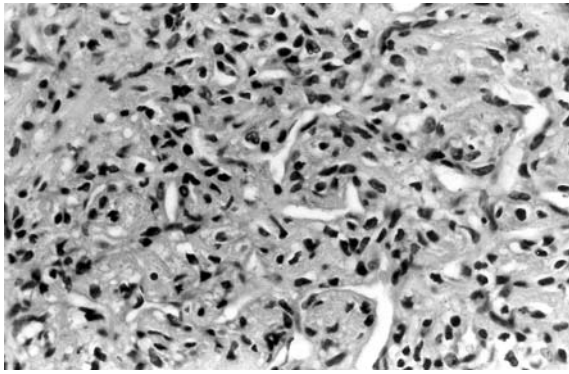
In regards to the preoperative imaging studies, after contrast administration, the CT scans of our patients showed hyperdense, homogeneously enhancing lesions. An obvious dural attachment of the tumor was noted in all the CT scans, as was abutting of the parenchyma. No evidence of calcification was seen in any of these tumors. Osteolysis of the adjacent bone was noted in 2/11 (18.2%) cases, while no hyperostosis was noted in any of our cases. In the obtained MRI studies, in three patients, lesions were hypo-intense on T<sub>1</sub>WI, while in the remaining five patients, the lesions appeared isointense on the same pulse sequence. On T<sub>2</sub>WI, the lesions were slightly hyperintense in the vast majority of the cases (7/8, 87.5%), while in one case the studied tumor appeared isointense. In all of our MRI studies, a significant amount of surrounding edema was evident. After the administration of Gd-DTPA, all these lesions were avidly enhancing. The angiographic findings of our cases revealed dual (ICA and ECA) feeding in 8/9 (88.9%) cases; in all of

our cases, numerous characteristic “corkscrew” vessels were noted. Interestingly, in 6/9 (66%) patients, early venous drainage was noted, while in the remaining patients no special venous drainage patterns were found. In two cases, invasion of the superior sagittal sinus was documented. Finally, the analysis of the obtained MR spectrum showed moderately increased concentrations of choline and myoinositol and mildly increased concentrations of lipids in 2/4 (50%) cases, while the concentrations of n-acetyl-aspartate (NAA) and phosphocreatine/creatine (PCr/Cr) were significantly decreased. The plain skull X-rays, whenever obtained, showed no abnormalities, with the exception of a single case in which osteolysis of the overlying parietal bone was noted.

The surgical resection of these tumors was characterized by their marked vascularity. Blood loss ranged between 250 and 1,850 ml, while the mean blood loss was 804.5 ml. It is worth noting that the average blood loss among patients with preoperative embolization was 508.3 ml, while blood loss in patients without any embolization was 1,160 ml. Our operative time ranged between 3 and 8 h, while our mean operative time was 5.0 h. The degree of resection, according to the scale proposed by Simpson, was grade I in 6/11 (54.5%) patients, grade II in 4/11 (36.4%), and grade IV in 1/11 (9.1%) patients. There was no operative mortality in our cases, and no intra- or early postoperative complications were encountered. One patient developed a superficial surgical wound infection which was managed successfully by surgical debridement and systemic antibiotic therapy and presented no further difficulties.

Macroscopically, the resected tumors were grayish-pink in color, quite firm and extremely vascular. Their microscopic examination showed very cellular tumors characterized by cytologic homogeneity and prominent mitotic activity; round to oval, dense cell populations with fusiform nuclei were recognized along with characteristic thin-walled “staghorn-shaped” capillaries (Fig. 1). In 4/11 (36.4%) of our cases, microcysts were identified. An extensive network of reticulin fibers was seen in all of our cases. No calcifications, psammoma bodies, or whorls were identified in any of our cases. Their immunohistochemical examinations showed that the resected lesions were EMA, cytokeratin, GFAP, S-100 protein, factor VIII related antigen and Ulex europaeus lectin negative; while also showing that they were positive for vimentin, CD34 and factor XIIIa. The examinations of the resected specimens by electron microscopy, demonstrated characteristic plump cells, lacking any cytoplasmic interdigitation or desmosomes.

In regards to local recurrence of the resected tumors, 3/11 (27.3%) patients were diagnosed as having one at a mean period of 5 years (range 2–7.5 years). One of these three patients underwent two additional craniotomies for recurrent tumor resection, while another patient had a second craniotomy to debulk his massive recurrent intracranial tumor which had intracranial and orbital components. The third patient chose to have no further treatment. Interestingly, the histology of the resected recurrent tumors remained unchanged compared to that of the original specimens.



**Fig. 1** Shows a histological section of a resected hemangiopericytoma stained with hematoxylin-eosin. Note the characteristic “staghorn” vascular channels surrounded by haphazardly arranged round and oval tumor cells. These tumor cells present indistinct cytoplasm borders and have fusiform nuclei. (H-E stain, magnification  $\times 132$ )

Extracranial metastatic disease was documented in 4/11 (36.4%) of our patients at a mean interval of 4.9 years (range 2.5–7 years) after their initial treatment. In two cases, the location of these metastases was in the lungs (solitary lesions), in one case it was in the liver (multiple lesions), and another patient was diagnosed with multifocal bone metastatic disease. One of these patients (liver metastases) was treated with chemotherapy (calcium folinate, doxorubicin, cisplatin, and fluorouracil) without success. One of the patients with a solitary lung metastatic lesion underwent a left-sided superior lobectomy while the other one refused to have any treatment.

The outcome of our patients according to the Glasgow Outcome Scale can be summarized as following: 7/11 (63.6%) patients scored 5, while 4/11 (36.4%) died at different points; the mean survival time, among this group of patients, was 5.5 (range 3–8 years).

## Discussion

The rarity of intracranial hemangiopericytomas and the imaging similarities of these tumors with meningiomas, make their prompt diagnosis quite challenging. Their differentiation is of paramount importance in the overall management of these patients, since the aggressive biological behavior and the poor prognosis of these tumors has been well established since their original descriptions [4, 10, 13–15, 27, 34, 35, 45, 84–86]. Despite their confusing imaging profile, hemangiopericytomas carry some epidemiologic characteristics that could potentially lead the clinician involved to their early diagnosis [4, 10, 15, 35, 45, 84]. It is widely accepted, that hemangiopericytomas, unlike meningiomas, are more common in males than females [10, 15, 33–35, 45]; a finding which was also observed in our series where males represented 63.6% of our patients. The male to female ratio is highly variable (1.1/1–1.5/1) among different series [35]; a variability which might well be explained by the small size of the

reported clinical series and the rarity of hemangiopericytomas compared to meningiomas (hemangiopericytomas represent only 2–4% of intracranial meningiomas [15, 35]). Clinical series with female predominance in patients with hemangiopericytoma have also been reported, indicating exactly the variability of the epidemiologic characteristics of these tumors [4, 27]. It has also been reported that the mean age at the time of diagnosis is lower in patients with hemangiopericytoma, compared to meningiomas [10, 15, 34, 35, 45]. In our series, this was 51.2 years, which was higher than the ones reported by other groups [34, 49, 77]. Although the vast majority of hemangiopericytomas occur in adults, approximately 10% of them occur in children, infants, and even fetuses [5, 16, 20, 39, 41]. Their infantile form represents tumors with a significantly more benign course [20, 39].

In regards to the clinical presentation of these patients, our findings are in agreement with the findings of previous series [4, 34, 45, 84]. The mean duration of symptoms was less than 4 months (17.6 weeks). Similarly, Alen et al. [4] reported a median interval of 3.1 months between initial symptoms and diagnosis, while Borg and Benjamin [13] reported a median of 7.5 months in their series. In all previously reported series, the duration of symptoms is shorter in patients with hemangiopericytomas compared to meningiomas [34, 45, 84]. Moreover, focal neurological deficits caused by hemangiopericytoma and signs and symptoms of increased intracranial pressure (as in our series) are significantly more common than seizures [13, 35]; a finding that can be explained by the rapid growth of hemangiopericytomas compared to meningiomas [13]. Intratumoral [15] or intracerebral hemorrhage [28], cranial nerve deficits [83], and even hyperprolactinemia and bitemporal hemianopsia [60] have been reported in the literature as presenting symptoms of hemangiopericytomas.

The location of intracranial hemangiopericytomas is quite similar to that of meningiomas [10, 35]. In our series, the most common location was the parasagittal plane. It is interesting, though, that hemangiopericytomas have been reported as being located in rather unusual locations such as in the orbit [2, 30, 51, 74], lateral ventricles (usually in the trigone) [36, 63], third ventricle (anterosuperior portion) [1], sellar/suprasellar areas [40, 59, 60, 74, 88], pineal body [64], Meckel’s cave [83], optic nerve sheath [12], sinuses [32] and their confluence [21], in brain parenchyma [4, 58, 70], and in the skull base, causing a Collet-Sicard syndrome [22, 79]. Although in our series all the tumors were supratentorial, the incidence of infratentorial lesions has been reported as being as high as 15% [68, 89].

Another point of controversy represents the absence of multicentricity among hemangiopericytomas; in all the previously published series and case reports, as well as in our current series, hemangiopericytomas always present as solitary lesions [4, 10, 13, 26, 27, 34, 35, 45, 84–86]. The widely accepted concept that multiple lesions always represent meningiomas (incidence of multiple meningiomas has been reported as high as 16% [10]), was questioned by Brunori et al. [15] when they reported a patient with mul-

multiple hemangiopericytomas; a finding, which might well be explained, though, by CSF seeding and not multicentricity [15, 55].

Despite the advances in neuroimaging, the differentiation of hemangiopericytoma from meningioma has remained a diagnostic dilemma [3, 10, 35, 66, 86]. Plain skull X-rays, in most cases, cannot differentiate between these similarly appearing intracranial, extra-axial tumors; the identification of reactive hyperostosis is indicative of meningioma, since hyperostosis has never been described in a hemangiopericytoma [35] before. In the cases, though, where osteolysis is noted, the diagnosis of meningioma cannot be excluded, since osteolysis could be secondary to bone remodeling, which is associated with meningiomas [75]. The CT scan in our series could not establish the diagnosis of a hemangiopericytoma. In our cases, we were unable to observe any of the CT specific features of hemangiopericytomas that have been previously described in the literature [3, 66, 75, 86]. It has been reported, that the dural attachment of a hemangiopericytoma is narrower than the one occurring in a meningioma [17]; unfortunately, we noticed no such difference in our series. In none of our cases, were we able to demonstrate “mushrooming” of the lesion (indicating most possibly parenchymal invasion) [56], or any irregularity in the shape of the hemangiopericytomas or any characteristic heterogeneous contrast enhancement [17]; on the contrary, the enhancement pattern of our cases was homogenous, even in the retrospective view of these CT scans. We could also not establish an association between hemangiopericytomas and the amount or the pattern of the surrounding edema, which was uniformly present in all of our cases. As far as we know, such an association has not been established, although in previous reports, it has been postulated that hemangiopericytomas usually demonstrates a mild to moderate amount of edema [4]. No calcifications were seen in any of our cases, a finding consistent with previously reported ones [17]. Unfortunately, there is a large percentage of meningiomas also not demonstrating calcification [75]. In addition, Alen et al., have reported the case of a hemangiopericytoma with calcification [4].

Our MRI studies, whenever available, were also not able to differentiate between these as being distinct from biological standpoint tumors; hemangiopericytomas present as isointense or hypointense lesions on T<sub>1</sub>WI, as in our series, and hyperintense or isointense on T<sub>2</sub>WI exactly as meningiomas do. In those cases where proton density pulse sequence was used, hemangiopericytoma appeared as a hyperintense lesion, exactly as most meningiomas appear. The <sup>1</sup>HMRS was very helpful in the few cases employed; the increased concentration of myoinositol in hemangiopericytomas, unlike meningiomas might be a pathognomonic, spectroscopic marker for hemangiopericytomas. Both meningiomas and hemangiopericytomas are also characterized by increased concentrations of choline and occasionally lipids, while the concentrations of NAA and PCr/Cr are decreased, as expected in extra-axial tumors. Our results confirmed the findings of Barba et al. [7] who, in a larger clinical series, found that the

spectroscopic signature of hemangiopericytoma is characterized by increased concentrations of myoinositol. Cho et al. [18], in a significantly smaller series, reported that hemangiopericytomas can be differentiated from meningiomas and schwannomas by <sup>1</sup>HMRS. However, their hemangiopericytoma spectroscopic profile was somewhat different than ours. It is apparent, that <sup>1</sup>HMRS is a promising, noninvasive diagnostic modality which might be helpful in differentiating hemangiopericytomas from meningiomas; further studies are required though for establishing an accurate and reproducible spectroscopic profile for hemangiopericytomas.

The angiographic characteristics of our cases (multiple “corkscrew” feeders, dual feeding of ICA and ECA origin) have been previously reported in the literature [23, 66, 75, 86]. The presence of feeders, mostly cortical, originating from the ICA, represents a strong indication for hemangiopericytoma, although there are reports of meningiomas with ICA feeders [86]. Interestingly, the most commonly observed venous-drainage pattern in our series (early drainage) was previously reported by other investigators [35, 75]; on the other hand, Alen et al. [4] found in their series that late venous drainage was more common. The role of angiography was also important in the evaluation of the compromise and infiltration of the adjacent superior sagittal sinus in our parasagittal cases; the accurate knowledge of the sinus invasion was very helpful in the safer surgical planning of these cases. Moreover, the employment of preoperative tumor embolization, whenever this was possible, was of great importance. We usually operate on these patients between the third and seventh postembolization day in order to avoid any embolization-induced edema and early development of collateral tumor circulation. In our study, PET was not available for the evaluation of these patients; however, DiChiro et al. [25] and Tsou et al. [84] have reported that hemangiopericytomas are characterized by a significant increase in the uptake of <sup>11</sup>C-methionine, hyperperfusion, and decreased glucose utilization [52]; these findings can help in distinguishing hemangiopericytomas from meningiomas. Furthermore, several clinical investigators have reported on the selective uptake of In-111 octreotide as a result of the expression of subtype 2 somatostatin receptors in meningiomas during scintigraphic or PET imaging [37, 38]. However, a slight uptake of In-111 labeled octreotide has also been reported for hemangiopericytomas [37, 38, 44]. Schmidt et al. proposed a four-tiered grading system of uptake; in their series, the uptake of meningiomas was significantly more massive than the one observed in hemangiopericytomas [76]. Newer markers such as Tc-99m have shown selectivity for meningiomas [37]. These emerging diagnostic methodologies appear to be clinically useful for differentiating hemangiopericytomas from meningiomas [37, 38, 44, 62, 76].

The diagnosis of hemangiopericytoma has remained a histologic one; therefore, the detailed pathologic examination of the resected tumors is of paramount importance not only for the establishment of the prompt diagnosis, but also for the appropriate further treatment of the patient. Our

findings were in agreement with the previously published, detailed histologic descriptions of hemangiopericytomas [10, 14, 15, 35, 39, 43, 47, 50, 69, 72, 83, 84]. One point that needs to be emphasized is the presence of reticulin in hemangiopericytomas; in all of our cases, as in the vast majority of the reported cases, a very wealthy network of reticulin was present [14]. However, it has been reported that reticulin might not be present, especially in highly cellular hemangiopericytomas [39]. The previously reported correlation between histology and the final outcome has remained ill defined [4]. Molecular genetic studies might enlighten this relationship in the near future; recently, the absence of the NF2 gene mutation, a commonly occurred gene mutation in meningiomas, was reported in hemangiopericytomas [46]. Additionally, hemangiopericytomas are characterized by deletion of the CDKN2A gene, which is not the case with meningiomas [65]. Further studies might identify a gene, or gene series, associated with the biologic behavior of this aggressive tumor.

The surgical management of these tumors becomes challenging due to their high vascularity. In our series, the mean operative blood loss was significantly lower than the one reported by Jaaskelainen et al. [45]. The role of preoperative embolization in decreasing the operative blood loss and its associated morbidity cannot be overemphasized. In our study, the blood loss among patients undergoing embolization was significantly lower (510 vs. 1,150 ml) compared to that observed in nonembolized patients; even though, the statistical significance of this finding is limited due to the limited size of our series, it is definitely indicative of the importance of this adjunctive modality. Although preoperative embolization in hemangiopericytomas might not be as effective as in typical meningiomas, it still represents a valuable option in the modern neurosurgical armamentarium [35]. In our series, there was no operative mortality as in the most recently reported series. However, in older clinical series, it has been reported up to 27% [35]; the usage of microsurgical techniques and preoperative embolization has minimized not only the operative mortality, but also the morbidity [4]. Our complete resection rate (grade I by Simpson) was 54.5%; the rates reported from various groups in the literature ranged between 50 and 67%, while Alen et al. [4] reported a complete resection rate of 83.3% in their series. Finally, in regards to the consistency of the resected tumors, in our series, all were solid lesions, as in the vast majority of the reported cases; however, cystic hemangiopericytomas have been reported in the literature [11, 42, 54].

Although the radiosensitivity of hemangiopericytomas has been questioned in the past by Jaaskelainen [45], the role of postoperative adjunct radiotherapy has been well established [33–35, 53, 85]. The treatment variable, most strongly related to the overall prognosis, is the administration of postoperative radiation therapy [35]. It is also widely accepted that the described dose of the radiation needs to be at least 50–55 Gy [35]. Interestingly, in their study, Dufour et al. [27] concluded that although external radiotherapy reduced the risk of local recurrence, it did not protect against neuraxis or peripheral metastasis. In the

same study, they advocate for the use of stereotactic radiosurgery in treating recurrent tumors whenever their size limit makes them treatable by this modality [27]. Similarly, in their series, Coffey et al. concluded that radiosurgery is effective in reducing the bulk of a recurrent hemangiopericytoma [19]. Although the preliminary reports of most investigators are quite promising, the role of radiosurgery in treating recurrent hemangiopericytomas needs to be defined. Another controversial issue is the use of preoperative external radiation for shrinking the tumor and making it surgically amenable, as reported by Fukui et al. [31]; the question that rises though, is how an accurate preoperative diagnosis can be established. In addition, it is widely accepted that operating on a previously irradiated tissue makes surgical manipulation more challenging.

It is well known that hemangiopericytomas have a tendency to recur locally [10, 14, 35, 67]. Interestingly, the extent of tumor removal has been less clearly correlated with the recurrence of hemangiopericytomas than for meningiomas [40, 49]. This might be explained by the tendency to aggressively irradiate partially resected tumors [35]. Guthrie et al. [34] calculated that the recurrence rate at 5, 10, and 15 years was 65, 76, and 87%, respectively. Schroder et al. [77], in an extensive review of the literature, found a recurrence-free interval of 50 months (range 1–26 years). More recently, Alen et al. [4] reported a 4/12 (33.4%) recurrence rate with a median recurrence-free interval of 65 months. Du et al. [26], reported only a 4/26 (3.8%) recurrence rate, but their follow-up time was very limited (average 22 months). In our series, the local recurrence rate was 3/11 (27.3%) at a mean period of 5 years (range 2–7.5 years). It is widely accepted that, after the first recurrence, hemangiopericytomas tend to recur at shorter intervals [35]. In their reported series, Guthrie et al. [34] found that the average time to second, third, and fourth operations for recurrence, was 38, 35, and 17 months, respectively. Additionally, they found that 53% of patients improved and 3% worsened after the first operation, while only 22% improved and 13% worsened after subsequent operations [34].

Intracranial hemangiopericytomas have the unique characteristic of giving extracranial metastases [35]. It is well known that they can give metastases in a delayed fashion that necessitates that “disease-free” patients not be considered “cured” [15, 35, 82]. Metastases appear at a mean period of 8 years after initial therapy, but there have even been cases reported where metastasis occurred 22 years after the initial treatment of the intracranial tumor (range 1–22 years) [4, 35]. The most common extracranial metastatic sites in order of their decreased frequency are: bones, liver, lungs, abdominal cavity, lymph nodes, skeletal muscle, kidney, pancreas, skin and subcutaneous tissue, breast, adrenal glands, gallbladder, diaphragm, retro-peritoneum, and heart [10, 35, 57, 72, 73, 78, 82, 87]. In our series, 4/11 (36.4%) patients were diagnosed with extracranial metastases at a mean period of 4.9 years (range 2.5–7 years) after the initial therapy of the intracranial tumors. Guthrie et al. [34] calculated that the probability of metastasis at 5, 10, and 15 years was 13, 33,

and 64% respectively. The very high probability of a delayed extracranial metastasis should alert the managing clinician and make him very suspicious of even vague symptomatology in these patients. Frequent clinical examinations, periodical chest x-rays, liver enzyme profiles, and even radionuclide bone scans (although it has been reported that bone metastases may not take up the isotope [72]) have been used for the follow-up of these patients [41]. The role of chemotherapy in the treatment of the metastatic hemangiopericytomas has remained very controversial; in a very limited number of series, the results, with some partial response to doxorubicin, were very disappointing [13]. Bastin et al. reported some benefit from an adriamycin-based chemotherapy protocol [8].

The 5-year survival rate in our series was 9/11 (81.8%). Guthrie et al. [34] calculated the median survival in their series after the first operation at 60 months, while their actuarial 5, 10, and 15-year survival rates were 67, 40, and 23% respectively. In their extensive review, Schroder et al. [77] calculated the 5, 10, and 15-year survival rate at 65, 45, and 15%. It is apparent that the rarity of the intracranial hemangiopericytomas along with the lack of a standardized treatment protocol has, as a result, highly variable survival, local recurrence, and extracranial metastasis rates. The establishment of a national or even international registry for intracranial hemangiopericytomas could potentially accumulate the required data for analysis and help in the development of evidence-based treatment guidelines for these highly aggressive tumors.

## Conclusion

Intracranial hemangiopericytomas represent a rare pathological entity. They usually present in a younger age than meningiomas, and there is an established male predominance. Plain skull X-rays and CT and MRI scans cannot accurately differentiate them from the similarly appearing meningiomas; however, proton MR spectroscopy and PET scanning appear to be helpful in their differential diagnosis. The establishment of the diagnosis of a hemangiopericytoma requires a histologic examination in which its distinct features can easily differentiate it from a meningioma. Although the reported clinical series are limited in size, their findings support the aggressive surgical resection of these tumors along with preoperative embolization, (whenever this is feasible), postsurgical radiation therapy at dosages higher than 50 Gy, and continuous surveillance of these “disease-free” but not “cured” patients for the early detection of delayed extracranial metastases. The role of stereotactic radiosurgery in the management of local intracranial recurrences, and the role of chemotherapy in the treatment of extracranial metastases needs to be defined. A national registry of intracranial hemangiopericytomas might be necessary for the development of more efficacious therapeutic guidelines.

## References

1. Abrahams JM, Forman MS, Lavi E, Goldberg H, Flamm ES (1999) Hemangiopericytoma of the third ventricle: case report. *J Neurosurg* 90:359–362
2. Ahn JY, Shim JY, Yang WI, Kim TS (2001) Meningeal solitary fibrous tumor as an unusual cause of exophthalmos: case report and review of the literature. *Neurosurg* 48:1362–1366
3. Akiyama M, Sakai H, Onoue H, Miyazaki Y, Abe T (2004) Imaging intracranial haemangiopericytomas: study of seven cases. *Neuroradiol* 46:194–197
4. Alen JF, Lobato RD, Gomez PA, Boto GR, Lagares A, Ramos A, Ricoy JR (2001) Intracranial hemangiopericytoma: study of 12 cases. *Acta Neurochir (Wien)* 143:575–586
5. Aouad N, Vital C, Rivel J, Ramsoubramanian K, Santosh S, Chowdry O (1991) Giant supratentorial meningeal haemangiopericytoma in a newborn. *Acta Neurochir* 112:154–156
6. Bailey P, Cushing H, Eisenhardt L (1928) Angioblastic meningiomas. *Arch Pathol* 6:953–990
7. Barba I, Moreno A, Martinez-Perez I, Tate AR, Cabanas ME, Baquero M, Capdevila A, Arus C (2001) Magnetic resonance spectroscopy of brain hemangiopericytoma: high myoinositol concentrations and discrimination from meningiomas. *J Neurosurg* 94:55–60
8. Bastin KT, Mehta MP (1992) Meningeal hemangiopericytoma: defining the role for radiation therapy. *J Neurooncol* 14:277–287
9. Begg CF, Garret R (1954) Hemangiopericytoma occurring in the meninges. *Cancer* 7:602–606
10. Berger MS and Kros JM (1996) Sarcomas and neoplasms of blood vessels: hemangiopericytomas (angioblastic meningioma). In: Youmans JR (ed) *Neurological surgery*, 4th edn. Saunders, Philadelphia, pp 2700–2703
11. Blank W, Spring A, Giesen H, Armann H (1988) Intracranial hemangiopericytoma in a child. *Klin Padiatr* 200:422–425
12. Boniuk M, Messmer EP, Font RL (1985) Hemangiopericytoma of the meninges of the optic nerve. *Ophthalmology* 92:1780–1787
13. Borg MF, Benjamin CS (1995) Haemangiopericytoma of the central nervous system. *Australas Radiol* 39:36–41
14. Bruner JM, Tien RD, Enterline DS (1998) Tumors of the meninges and related tissues: hemangiopericytomas of the meninges. In: Bigner DD, McLendon RE, Bruner JM (eds) *Russell and Rubinstein’s pathology of tumors of the nervous system*, 6th edn. Arnold, London, pp 112–117
15. Brunori A, Delitala A, Oddi G, Chiappetta F (1997) Recent experience in the management of meningeal hemangiopericytomas. *Tumori* 83:856–860
16. Cavalheiro S, Sparapani F, Moron AF, Silva M, Stavale JN (2002) Fetal meningeal hemangiopericytoma. *J Neurosurg* 97:1217–1220
17. Chiechi MV, Smirniotopoulos JG, Mena H (1996) Intracranial haemangiopericytomas: MR and CT features. *AJNR* 17:1365–1371
18. Cho YD, Choi GH, Lee SP, Kim JK (2003) <sup>1</sup>H MRS metabolic patterns for distinguishing between meningiomas and other brain tumors. *Magn Reson Imaging* 6:663–672
19. Coffey RJ, Cascino TL, Shaw EG (1993) Radiosurgical treatment of recurrent haemangiopericytomas of the meninges: preliminary results. *J Neurosurg* 78:903–908
20. Cole JC, Naul LG (2000) Intracranial infantile hemangiopericytoma. *Pediatr Radiol* 30:271–273
21. Collignon FP, Cohen-Gadol AA, Piepgras DG (2003) Hemangiopericytoma of the confluence of sinuses and the transverse sinuses. *J Neurosurg* 99:1085–1088
22. Comacchio F, Eredita R, Poletto E, Poletti A, Marchiori C (1995) Hemangiopericytoma of the skull base and Collet-Sicard syndrome: a case report. *Ear Nose Throat J* 74:845–847

23. Cosentino CM, Poulton TB, Esguerra JV, Sands SF (1993) Giant cranial hemangiopericytoma: MR and angiographic findings. *AJNR* 14:253–256
24. Cushing H, Eisenhardt L (1938) Meningiomas: their classification regional behavior, life history, and surgical end results. Thomas, Springfield, Illinois
25. Di Chiro G, Hatazawa J, Katz DA, Rizzoli HV, De Michele DJ (1987) Glucose utilization by intracranial meningiomas as an index of tumor aggressivity and probability of recurrence: a PET study. *Radiology* 167:521–526
26. Du GH, Zhou LF, Li SQ, Mao Y, Chen H (2001) Management of hemangiopericytomas in the central nervous system. *Chin Med J* 114:795–798
27. Dufour H, Metellus P, Fuentes S, Murracchiole X, Regis J, Figarella-Branger D, Grisoli F (2001) Meningeal hemangiopericytoma: a retrospective study of 21 patients with special review of postoperative external radiotherapy. *Neurosurgery* 48:756–763
28. Feldman ZT, Reichenthal E, Zucker G, Greiff M (1991) Haemangiopericytoma presenting with intracerebral haemorrhage: case report and review of literature. *Acta Neurochir* 112:151–153
29. Fisher ER, Davis JS, Lemmen LJ (1958) Meningeal hemangiopericytoma. *Arch Neurol Psychiat* 79:40–45
30. Fu ER, Goh SH, Fong CM (1993) Case report of primary orbital hemangiopericytoma. *Ann Acad Med Singap* 22:966–968
31. Fukui M, Kitamura K, Takaki T, Kinoshita K, Watanabe K, Mihara K (1977) Radiosensitivity of meningioma: analysis of five cases of highly vascular meningioma treated by preoperative irradiation. *Acta Neurochir (Wien)* 36:47–60
32. Goel A, Muzumdar D, Desai K, Chagla A (2003) Retroorbital hemangiopericytoma and cavernous sinus schwannoma. *Neurol Med Chir (Tokyo)* 43:47–50
33. Goellner BL, Ebersold MJ, Scheithauser BW, Shaw EG (1989) Meningeal hemangiopericytoma: histopathological features, treatment, and long-term follow-up of 44 cases. *Neurosurgery* 70:375–380
34. Guthrie BL, Ebersold MJ, Scheithauser BW, Shaw EG (1989) Meningeal hemangiopericytomas: histopathological features, treatment, and long-term follow-up of 44 cases. *Neurosurgery* 25:514–522
35. Kaye AH, Laws ER (eds) (1995) *Brain Tumors*. Livingstone, Tokyo pp 705–711
36. Hattingen E, Pilatus U, Good C, Franz K, Lanfermann H, Zanella FE (2003) An unusual intraventricular haemangiopericytoma: MRI and spectroscopy. *Neuroradiol* 45:386–389
37. Hellwig D, Samnick S, Reif J, Romeike BF, Reith W, Moringlane JR, Kirsch CM (2002) Comparison of tc-99m depreotide and In-111 octreotide in recurrent meningioma. *Clin Nucl Med* 27(11):781–784
38. Henze M, Schuhmacher J, Hipp P, Kowalski J, Becker DW, Doll J, Macke HR, Hofmann M, Debus J, Haberkorn U (2001) PET imaging of somatostatin receptors using [68GA] DOTA-D-Phel-Tyr3-octreotide: first results in patients with meningiomas. *J Nucl Med* 42(7):1053–1056
39. Herzog CE, Leeds NE, Bruner JM, Baumgartner JE (1995) Intracranial hemangiopericytoma in children. *Pediatr Neurosurg* 22:274–279
40. Horten BC, Ulrich H, Rubinstein LJ, Montague SR (1977) The angioblastic meningioma: a reappraisal of a nosological problem. *J Neurol Sci* 31:387–410
41. Huisman TAGM, Brandner S, Niggli F, Kaci G, Willi UV, Martin E (2000) Meningeal hemangiopericytoma in childhood. *Eur Radiol* 10:1073–1075
42. Itoyama Y, Seto H, Nagahiro S, Kuratsu J, Uemura S, Ushio Y (1991) Intracranial cystic hemangiopericytoma: case report. *Neurol Med Chir (Tokyo)* 31:210–213
43. Iwaki T, Fukui M, Takeshita M, Tsuneyoshi M, Tateishi J (1988) Hemangiopericytoma of the meninges: a clinicopathologic and immunohistochemical study. *Clin Neuropathol* 7:93–99
44. Jan de Beur SM, Streeten EA, Cevelek AC, McCarthy EF, Uribe L, Marx SJ, Onobrakpeya O, Raisz LG, Watts NB, Sharon M, Levine MA (2002) Localisation of mesenchymal tumours by somatostatin receptor imaging. *Lancet* 2 359 (9308):761–763
45. Jaaskelainen J, Servo A, Haltia M, Wahlstrom T, Valtonen S (1985) Intracranial hemangiopericytoma: radiology, surgery, radiotherapy, and outcome in 21 patients. *Surg Neurol* 23:227–236
46. Joseph JT, Lisle DK, Jacoby LB, Paulus W, Barone R, Cohen M, Roggendorf WH, Bruner JM, Gusella JF, Louis DN (1995) NF2 gene analysis distinguishes hemangiopericytoma from meningioma. *Am J Pathol* 147:1450–1455
47. Kanazawa T, Nishino H, Miyata M, Kuriki K, Abe K, Ichimura K (2001) Pathology in focus: haemangiopericytoma of infratemporal fossa. *J Laryngol Otol* 115:77–79
48. Kernohan JW, Uihlein A (1962) *Sarcomas of the brain*. Thomas, Springfield Ill
49. Kochanek S, Schroder R, Firsching R (1986) Hemangiopericytoma of the meninges. I. Histopathological variability and differential diagnosis. *Zentralbl Neurochir* 47:183–190
50. Kochi N, Tani E, Kaba K, Natsume S (1984) Immunohistochemical study of fibronectin in hemangioblastomas and hemangiopericytomas. *Acta Neuropathol* 64:229–233
51. Kolawole TM, Patel PJ, Boshra Y, Ur-Rahman N (1988) Orbital and intracranial haemangiopericytoma. *Eur J Radiol* 8:106–108
52. Kracht LW, Bauer A, Herholz K, Terstegge K, Friese M, Schroder R, Heiss WD (1999) Positron emission tomography in a case of intracranial hemangiopericytoma. *J Comput Assist Tomogr* 23:365–368
53. Kruse F (1961) Hemangiopericytoma of the meninges (angioblastic meningioma of Cushing and Eisenhardt): clinicopathologic aspects and follow-up studies of 8 cases. *Neurology* 11:771–777
54. Kuzeyli K, Cakir E, Karaarslan G, Usul H, Reis A, Baykal S, Dinc H, Sari A (2003) Primary parenchymal cerebral cystic haemangiopericytoma: a 5-year follow-up of disease progression. *Australas Radiol* 47:88–91
55. Larson JJ, Tew JM, Simon M (1995) Evidence for clonal spread in the development of multiple meningiomas. *J Neurosurg* 83:705–709
56. Marc JA, Takei Y, Schechter MM, Hoffman JC (1975) Intracranial haemangiopericytomas. angiography, pathology and differential diagnosis. *Am J Roentgenol* 125:823–831
57. Masui T, Kurosawa Y, Iwase T, Sugimura H, Isoda H, Takahashi M, Mochizuki T, Takinami M (1996) Meningeal hemangiopericytoma metastatic to the heart. *Radiat Med* 14:91–94
58. McDonald JV, Terry R (1962) Hemangiopericytoma of the brain. *Neurology* 11:497–502
59. Mena H, Ribas JL, Pezeshkpour GH, Cowan DN, Parisi JE (1991) Hemangiopericytoma of the central nervous system: a review of 94 cases. *Human Pathol* 22:84–91
60. Morrison DA, Bibby K (1997) Sellar and suprasellar hemangiopericytoma mimicking pituitary adenoma. *Arch Ophthalmol* 115:1201–1203
61. Muller J, Mealey J (1971) The use of tissue culture in differentiation between angioblastic meningioma and hemangiopericytoma. *J Neurosurg* 34:341–348
62. Muller V, Klutmann S, Clausen M (2003) Somatostatin receptor scintigraphy in a patient with metastatic hemangiopericytoma. *Nuklearmedizin* 42(3):N13–N14
63. Muttaqin Z, Uozumi T, Kuwabara S et al (1991) Intraventricular hemangiopericytoma: case report. *Neurol Med Chir* 31:662–665
64. Olson JR, Abell MR (1969) Haemangiopericytoma of the pineal body. *J Neurol Neurosurg Psychiatry* 32:445–449
65. Ono Y, Ueki K, Joseph JT and Louis DN (1996) Homozygous deletions of the CDKN2/p16 gene in dural hemangiopericytomas. *Acta Neuropathol* 91:221–225

66. Osborne DR, Dubois P, Drayer B, Sage M, Burger P, Heinz ER (1981) Primary intracranial meningeal and spinal hemangiopericytoma: radiologic manifestations. *AJNR* 2:69–74
67. Palkovic S (1987) Multiple recurrence of an intracranial hemangiopericytoma. *Neurosurg Rev* 10:233–236
68. Payne BR, Prasad D, Steiner M, Steiner L (2000) Gamma surgery for hemangiopericytomas. *Acta Neurochir (Wien)* 142:527–537
69. Pena CE (1975) Intracranial hemangiopericytoma: ultrastructural evidence of its leiomyoblastic differentiation. *Acta Neuropathol (Berl)* 33:279–284
70. Pitkethly D, Hardeman J, Kempe L, Earle K (1970) Angioblastic meningiomas: clinicopathologic study of 81 cases. *J Neurosurg* 32:539–544
71. Popoff NA, Malinin T, Rosomoff HL (1974) Fine structure of intracranial hemangiopericytoma and angiomatous meningioma. *Cancer* 34:1187–1197
72. Prakasha B, Jacob R, Dawson A, Joannides T (2001) Haemangiopericytoma diagnosed from a metastasis 11 years after surgery for “atypical meningioma”. *Brit J Radiol* 74:856–858
73. Radley MG, McDonald JV (1992) Meningeal hemangiopericytoma of the posterior fossa and thoracic spinal epidural space: case report. *Neurosurg* 30:446–452
74. Rusalleda J, Feliciani M, Avila A, Castaner E, Guardia E, Juan M (1994) Neuroradiological features of intracranial and intraorbital meningeal haemangiopericytomas. *Neuroradiol* 36:440–445
75. Saunders WP, Chundi V (2000) Extra-axial tumors including pituitary and parasellar. In: Orrison W Jr (ed) *Neuroimaging*. Saunders, Philadelphia, pp 612–717
76. Schmidt M, Scheidhauer L, Luyken C, Voth E, Hildebrandt G, Klug N, Schicha H (1998) Somatostatin receptor imaging in intracranial tumours. *Eur J Nucl Med* 25(7):675–686
77. Schroder R, Firsching R, Kochanek S (1986) Hemangiopericytoma of the meninges. II. General and clinical data. *Zentralbl Neurochir* 47:191–199
78. Scott M, Kellet G, Peale A (1974) Angioblastic meningioma (hemangiopericytoma) of the cerebellar fossa with metastases to the temporal bone and the lumbar spine. *Surg Neurol* 2:35–38
79. Sehitoglu MA, Uneri C, Celikoyar MM, Tutkun A, Kullu S (1990) Hemangiopericytoma as the cause of Collet-Sicard syndrome. *ORL* 52:133–136
80. Simpson D (1957) The recurrence of intracranial meningiomas after surgical treatment. *J Neurol Neurosurg Psychiatry* 20:22–39
81. Stout AP, Murray MR (1942) Hemangiopericytoma: a vascular tumor featuring Zimmerman’s pericyte. *Ann Surg* 116:26–33
82. Suzuki H, Haga Y, Oguro K, Shinoda S, Masuzawa T, Kanai N (2002) Intracranial hemangiopericytoma with extracranial metastasis occurring after 22 years. *Neurol Med Chir* 42:297–300
83. Tan I, Soo M, Ng T (2001) Haemangiopericytoma of the trigeminal nerve. *Australas Radiol* 45:350–353
84. Tsou H, Wang Y, Yang D, Wei S (2002) Intra-extracranial hemangiopericytoma: clinical manifestations, histopathological feature, diagnosis, treatment, and outcomes. *Chin Med J (Taipei)* 65:314–319
85. Uemura S, Kuratsu J, Hamada J, Yoshioka S, Kochi M, Ushio Y, Nakahara T, Kishida K (1992) Effect of radiation therapy against intracranial hemangiopericytoma. *Neurol Med Chir* 32:328–332
86. Uttley D, Clifton AC (1995) Haemangiopericytoma: a clinical and radiological comparison with atypical meningiomas. *Brit J Neurosurg* 9:127–134
87. Woitzik J, Sommer C, Krauss JK (2003) Delayed manifestation of spinal metastasis: a special feature of hemangiopericytoma. *Clin Neurol Neurosurg* 105:159–166
88. Yokota M, Tani ET, Maeda Y, Morimura T, Kakudo K, Uematsu K (1985) Acromegaly associated with suprasellar and pulmonary hemangiopericytomas. *J Neurosurg* 2:767–771
89. Younis GA, Sawaya R, DeMonte F, Hess KR, Albrecht S, Bruner JM (1995) Aggressive meningeal tumors: review of a series. *J Neurosurg* 82:17–27