

Combined transarticular lateral and medial approach with partial facetectomy for lumbar foraminal stenosis

Technical note

NEDAL HEJAZI, M.D., ALFRED WITZMANN, M.D., KLAUS HERGAN, M.D.,
AND WERNER HASSLER, M.D.

*Department of Neurosurgery, Willkommen im Landeskrankenhaus, Feldkirch, Austria;
and Department of Neurosurgery, Klinikum Kalkweg, Duisburg, Germany*

✓ The authors performed a microsurgical combined transarticular lateral and medial procedure with partial facetectomy in 24 patients (16 men and nine women) with lumbar intervertebral foraminal stenosis to decompress the affected nerve root. The goal of this surgery was to maintain the integrity of the facet joint, to guarantee satisfactory exploration, and to obtain a sufficient decompression of the intervertebral foramen. Because only minimal bone resection is required, the risk of secondary instability induced by complete facetectomy is avoided. The clinical results of this procedure were excellent in the majority of cases. The mean follow-up period was 21.8 months.

KEY WORDS • facetectomy • lumbar spine • radiculopathy

LATERAL spinal canal stenosis is a common cause of lumbar radicular pain. An 8 to 11% incidence of lateral root entrapment has been reported. Unfortunately, unrecognized or recurrent foraminal stenosis may be associated with failed-back surgery syndrome.^{7,9} Burton, et al.,² in their review of failed-back surgery syndrome, attributed this phenomenon to the lack of recognition or inadequate treatment of nonspecific lateral canal stenosis, and they considered it to be the cause of pain in nearly 60% of patients in whom symptoms continued postoperatively. Therefore, lumbar foraminal stenosis is an important pathological entity to identify in the patient being treated for radicular symptoms. Several authors have advocated complete removal of the facet joint to allow for decompression of the spinal canal and exploration of the intervertebral foramen.^{1,3,4,7,8,11} These factors may result in spinal instability and occasionally require a posterolateral fusion.^{3,7,11} We performed a microsurgical transarticular combined lateral and medial procedure with partial facetectomy in 24 patients with lumbar intervertebral foraminal stenosis to explore and decompress the affected nerve roots. The goal of this procedure was to maintain the integrity of the facet joint, ensure sufficient exploration, and obtain sufficient decompression of the lumbar foramen.

Surgical Technique

An x-ray film is obtained to verify the correct position of the incision. The facet joint and the adjacent superior

Abbreviations used in this paper: CT = computerized tomography; MR = magnetic resonance.

and inferior laminae are exposed by making a paramedian or horizontal incision. Using an operating microscope and a high-speed drill, the superolateral portion of the facet joint and the upper and lateral margin of the interarticular part were drilled away. The amount of facet joint resection should not exceed 50%. Afterward, the intertransverse ligament is excised to expose the nerve root lateral to the foramen. The affected nerve root is then followed along the neuroforamen. Decompression of the medial part of the foramen is then completed using the standard interlaminar approach. Sufficient nerve root decompression must be carefully confirmed using a small nerve hook (Fig. 1). This may be done by moving the hook from the medial and lateral sides through the foramen and then laterally. In using this combined approach, we were also able to reach and decompress two nerve roots, if necessary. The superior nerve root is decompressed by removing the superolateral portion of the facet joint and upper and lateral margin of the interarticularis, and the inferior nerve root is decompressed by removing the medial part of the facet and part of the lamina.

Results

Twenty-four patients with one- or two-level radiculopathy secondary to lumbar foraminal stenosis and refractory to conservative treatment underwent surgery between 1997 and 1999. These 24 procedures represented approximately 2% (24 of 1232) of all lumbar spinal surgeries performed during that period. Patients with disc herniation were excluded from the study. The patient population con-

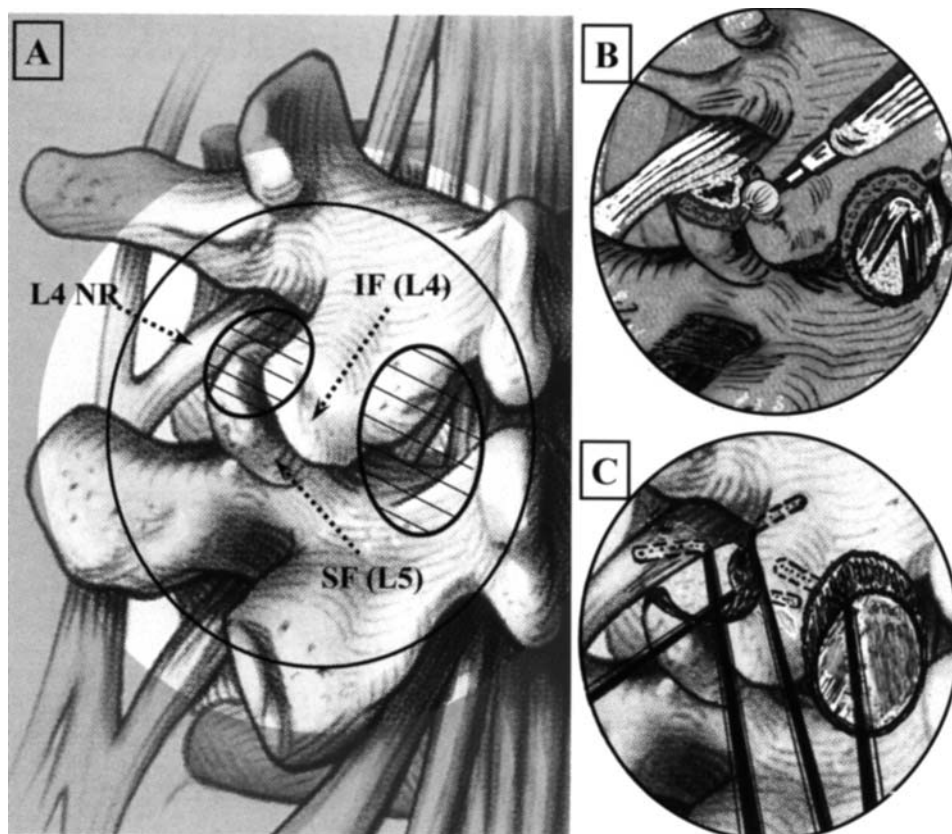


FIG. 1. Anatomical diagram showing the area of the combined transarticular lateral and medial partial facetectomy approach for lumbar foraminal stenosis. A and B: Using an operating microscope and a high-speed drill, the superolateral portion of the facet joint and the superolateral margin of the interarticular part were drilled away. Decompression of the medial portion of the foramen is then completed using the standard interlaminar approach. Note the preservation of the main portion of the facet joint to reduce the possibility of postoperative instability. C: Sufficient nerve root decompression must be carefully confirmed using a small nerve hook. This can be accomplished by moving the hook from the medial and the lateral sides through the foramen and then laterally. NR = nerve root; IF = inferior facet; SF = superior facet.

sisted of 16 men and nine women who ranged in age from 25 to 72 years (mean 53.3 years). The most common nerve roots involved were the L-5 nerve root (18 patients [75%]), the L-4 nerve root (three patients), the L-3 nerve root (two patients), and the L-2 nerve root (one patient). Two-level radiculopathy was presented in eight cases (33%). Back pain was also present in 18 patients. A motor deficit was detected in nine patients, and 14 experienced reflex abnormalities. The diagnosis was made by performing CT scanning and MR imaging in all patients. The findings suggestive of stenosis on reconstructed CT scans included the presence of bone spurs arising from the posterolateral vertebral body or articular facet and extending into the foramen. The MR imaging studies revealed a foramen of diminished size and a paucity of perineural fat surrounding the nerve root on T₁-weighted sequences (Fig. 2A and B). The follow-up period ranged from 15 to 43 months (mean 21.8 months). Outcome was defined as excellent (no pain), good (some back pain), fair (moderate radiculopathy), and poor (unchanged or worse) based on the Macnab classification.¹⁰ The results were excellent in 21 patients, good in two, and fair in one. There were no

surgery-related complications. Lateral lumbar spine flexion-extension radiography was performed in all patients at various times ranging from 3 to 48 months after the surgery, and no evidence of postoperative spinal instability was found. Postoperative three-dimensional reconstructed CT scanning demonstrated the preservation of the main portion of the lumbar facet joint (Fig. 2C).

Discussion

Different surgical approaches have been used to reach the extraforaminal lateral area of the lumbar spine.^{3,6,11,12} Several authors have advocated the complete removal of the facet joint to allow for decompression of the spinal canal and exploration of the intervertebral foramen. These steps, however, may result in spinal instability and occasionally require posterolateral fusion.^{3-5,7} In their patients, Abdullah, et al.,¹ removed the medial part of the facet and undermined the lateral portion with a drill. The drawbacks of this medial subtotal facetectomy are poor visual control and the risk of incomplete decompression of the lateral foramen. Reulen, et al.,¹⁴ have demonstrated that in the

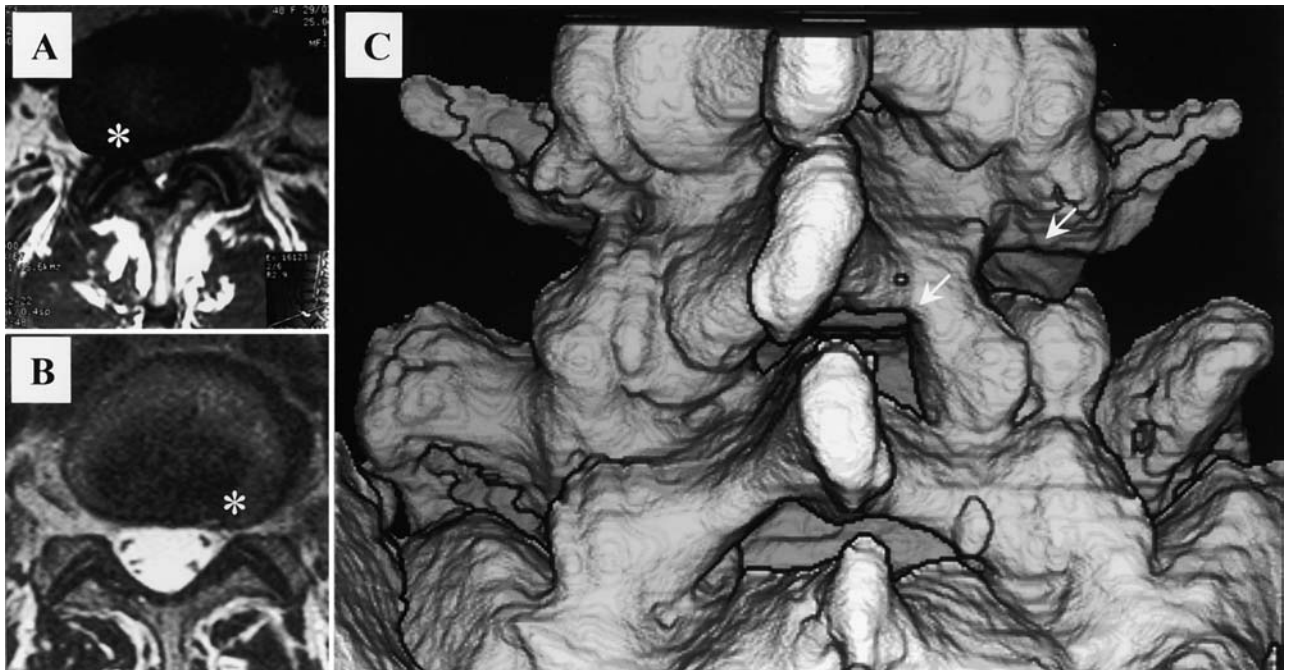


FIG. 2. A and B: Preoperative T₁-weighted MR images obtained at level L4–5 on the right side (A) and L5–S1 on the left side (B) revealing a foramen of diminished size and the paucity of perineural fat surrounding the nerve root (*asterisks*). C: Three-dimensional reconstructed CT scans of the lumbar spine obtained 6 weeks postoperatively. *Arrows* indicate L4–5 level on the right. Note preservation of the main portion of the facet joint and the good visual control of the superior and inferior nerve root.

majority of the cases most of the base of the inferior articular process of the superior vertebral body had to be removed to decompress the nerve root. This bone removal may weaken the base of the articular process and may result in fracture and significant postoperative spinal instability.⁵ Clinical studies of the treatment of intra- and extraforaminal nerve root compression have shown that patients in whom postoperative clinical status is poor were those who underwent total facetectomy or resection of the pars interarticularis alone, without spinal fusion.⁷ Some authors therefore have declared that spinal fusion is mandatory whenever total facetectomy is required.^{3,7,9} Epstein³ has also expressed belief that primary fusion should be considered in patients who undergo total facetectomy. Even in the absence of significant manifest spinal instability, the total facetectomy creates altered paths of loading in the three columns of the spine, which may cause significant postoperative low-back pain due to degeneration in the adjacent discoligamentous structures.^{5,12,13} Although facet joint destruction will not produce acute instability, it will transfer the loads to the adjacent disc and conceivably accelerate its degeneration.⁵ According to Kunogi and Hasue,⁷ of eight patients with intra- or extraforaminal disc herniations who underwent total facetectomy, a fusion procedure was necessary in two (25%). The procedure described here allows for preservation of the main portion of the facet joint and provides good access to and visual control of the nerve root (or two nerve roots, if necessary), as well as the lateral and the medial part of the intervertebral foramen, with minimal risk of nerve root in-

jury because of the improved visualization. The superior nerve root is decompressed by removing the superolateral portion of the facet joint and the superolateral margin of the interarticularis, and the inferior nerve root is decompressed by removing the medial part of the facet and part of the lamina. The preservation of a functional facet joint reduces the possibility of postoperative instability. The clinical results of this procedure were excellent in the majority of cases.

Conclusions

The procedure described in this paper is safe and minimally invasive, providing excellent visualization of the lateral spinal structures. Because only minimal bone resection is required, the risk of secondary instability due to complete facetectomy is avoided.

References

1. Abdullah AF, Wolber PG, Warfield JR, et al: Surgical management of extreme lateral lumbar disc herniations: review of 138 cases. *Neurosurgery* **22**:648–653, 1988
2. Burton CV, Kirkaldy-Willis WH, Yong-Hing K, et al: Causes of failure of surgery on the lumbar spine. *Clin Orthop* **157**: 191–197, 1981
3. Epstein NE: Evaluation of varied surgical approaches used in the management of 170 far-lateral lumbar disc herniations: indications and results. *J Neurosurg* **83**:648–656, 1995
4. Garrido E, Connaughton PN: Unilateral facetectomy approach

Microsurgery in lumbar foraminal stenosis

- for lateral lumbar disc herniation. **J Neurosurg** **74**:754–756, 1991
5. Hafer TR, O'Brien M, Dryer JW, et al: The role of the lumbar facet joints in spinal stability. **Spine** **19**:2667–2670, 1994
 6. Hassler W, Brandner S, Slansky I: Microsurgical management of lateral lumbar disc herniations: combined lateral and interlaminar approach. **Acta Neurochir (Wien)** **138**:907–910, 1996
 7. Kunogi J, Hasue M: Diagnosis and operative treatment of intraforaminal, extraforaminal nerve root compression. **Spine** **16**:1312–1330, 1991
 8. Lee CK, Rauschnig W, Glenn W: Lateral lumbar spinal canal stenosis: classification, pathologic anatomy, surgical decompression. **Spine** **13**:313–320, 1988
 9. Jenis LG, An HS: Spine update. Lumbar foraminal stenosis. **Spine** **25**:389–394, 2000
 10. Macnab I: Negative disc exploration. An analysis of the causes of nerve-root involvement in sixty-eight patients. **J Bone Joint Surg (Am)** **53**:891–903, 1971
 11. O'Brien MF, Peterson D, Crockard HA: A posterolateral microsurgical approach to extreme-lateral lumbar disc herniation. **J Neurosurg** **83**:636–640, 1995
 12. Porchet F, Chollet-Bornand A, De Tribolet N: Long term follow up of patients surgically treated by the far lateral approach for foraminal and extraforaminal lumbar disc herniations. **J Neurosurg (Spine 1)** **90**:59–66, 1999
 13. Rauschnig W: Normal and pathologic anatomy of the lumbar root canals. **Spine** **12**:1008–1019, 1987
 14. Reulen H, Muller A, Ebeling U: Microsurgical anatomy of the far lateral approach of the extraforaminal lumbar disc herniations. **Neurosurgery** **39**:345–350, 1996

Manuscript received November 27, 2000.

Accepted in final form August 24, 2001.

Address reprint requests to: Nedal Hejazi, M.D., Department of Neurosurgery, LKH Feldkirch, Carinagasse 49, A-6800 Feldkirch, Austria. email: hejazi@dr.com.