

Spine

## Cage containing a biphasic calcium phosphate ceramic (Triosite) for the treatment of cervical spondylosis

Der-Yang Cho, MD\*, Wuen-Yen Lee, MD,  
Pon-Chun Sheu, MD, Chun-Chung Chen, MD

Department of Neurosurgery, China Medical University Hospital, Taichung, Taichung, Taiwan 404, Republic of China

Received 1 March 2004; accepted 5 October 2004

### Abstract

**Background:** We evaluated the fusion efficacy and clinical outcomes of a cage containing a biphasic calcium phosphate ceramic (Triosite) in treating cervical spondylosis.

**Methods:** We randomly divided 100 patients with cervical spondylosis undergoing anterior discectomy with interbody polyetheretherketone (PEEK) fusion into 2 groups in the past 2 years: group A (n = 50), PEEK cage containing a biphasic calcium phosphate ceramic (Triosite), and group B (n = 50), PEEK cage containing an autogenous iliac bone graft. We compared the fusion rate, fusion time, spinal curvature, and neuroforamen size between the 2 groups. We also compared excess operation time, excess blood loss, hospital stay, complications, and neurological recovery status between the groups.

**Results:** The fusion rates were 57%, 67%, 77%, 82%, 92%, and 100% in group A and 81%, 86%, 95%, 95%, 100%, and 100% in group B in the first 6 postoperative months. The fusion rate in group A was significantly lower than that in group B in the first 5 months after the procedure ( $P < .05$  and  $P < .01$ , respectively), but the fusion rate reached 100% in both groups by the sixth month. Within the first 6 months, as the fusion level increased, the fusion rates reduced and time to fusion was delayed in both groups. There were no donor site complications in group A. However, 3 patients (6%) from group B experienced complications (1, wound infection; 1, numbness of thigh; and 1, subcutaneous hematoma) ( $P < .001$ ). The hospital stay was shorter in group A ( $4.43 \pm 2.36$  days) than in group B ( $7.00 \pm 3.77$  days) ( $P = .001$ ). The mean excessive blood loss and excessive operative time for an iliac bone graft in group B were  $15 \pm 5$  mL and  $10 \pm 6$  minutes. There was no statistical significance in spinal curve correction, neuroforamen enlargement, and neurological recovery.

**Conclusions:** A cage containing a biphasic calcium phosphate ceramic resulted in complete fusion by the sixth postoperative month, although the fusion rate was lower than that in a cage containing an autograft during the first 5 months after the operation and the time to fusion was delayed. Using a cage containing a biphasic calcium phosphate ceramic leads to a shorter hospital stay, less blood loss, shorter operative time, and no donor site complications. It seemed to be a good substitute for cervical spondylotic fusion.

© 2005 Elsevier Inc. All rights reserved.

### Keywords:

Autograft; Biphasic Calcium Phosphate Ceramic; Cage; Cervical spondylosis; Hydroxyapatite; Time to fusion; Polyetheretherketone (PEEK); Triosite

### 1. Introduction

Interbody cervical fusion with an iliac autograft is an effective treatment for degenerative cervical diseases [32]. It does not only provide an enlarged neuroforamen but also offers solid spinal fusion. However, 2 major pitfalls from the

\* Corresponding author. Tel.: +886 42 2052121x4434; fax: +886 42 2052121x4435.

E-mail address: [d5057@www.cmuh.org.tw](mailto:d5057@www.cmuh.org.tw) (D.-Y. Cho).

Table 1  
Demographic data of cervical spondylosis

	Group A (n = 50)	Group B (n = 50)
M/F	24:26	28:22
One level	15	17
Two levels	7	13
Three levels	28	20
Total levels	113	103
C2-C3	1	0
C3-C4	9	8
C4-C5	18	18
C5-C6	26	24
C6-C7	12	8
Radiculopathy	18	18
Myelopathy	12	10
Radiculomyelography	10	12

There are no statistical differences in each item between the groups.

iliac bone graft were noted: graft physical characteristics and donor site complications. Graft collapse, nonunion, and dislodgement were the major graft-itself problems [3,11,38,42]. An et al [2] reported a 23.7% autograft collapse rate. Lordosis caused by graft collapse to induce neck pain is a severe complication of autograft fusion. As the fusion level increases, the nonunion rate increases. For one-level fusion, Robinson et al [33] reported a 12% rate of nonunion, which increased to 27% for two-level fusion and to 50% for three-level fusion. Donor site complications may cause other important postoperative morbidities [21,44]. DePalma et al [9] reported that 9% of acute complications including hematoma and wound infection were related to the iliac donor site. Donor site pain persisting for more than 3 months has been reported in up to 15% [36]. Ghent [12] reported that up to 10% of patients suffer from lateral cutaneous nerve injury during iliac bone graft harvesting, leading to dyesthesia in a large area on the lateral aspect of the thigh.

Previous studies have reported that hydroxyapatite (HA) and tibial allograft for cervical spinal fusion prevented donor site complication [4,6,7,13]. However, the graft collapse, dislodgement, and nonunion rate were very high especially in cases with a pure HA graft [34,37,45,46]. An et al [2] reported that a free-dried allograft plus demineralized bone matrix had a 46.2% nonunion rate in one-level fusion and up to a 75% nonunion rate in three-level fusion.

An allograft also carries bacterial contamination and viral transmission risks [39].

A PEEK cage containing an autograft may solve some of the problems associated with autograft [5,20]. However, hospital stay may be prolonged because of donor site problems [5]. In a goat model, Mooney et al [23] reported that a cage containing HA granules produced the same amount of new bone ingrowth as a cage containing an autograft did. In a clinical study, using a cage containing a ceramic as an osteoconductive matrix for cervical spinal fusion was rarely reported. Therefore, we evaluated the efficacy and outcome of a PEEK cage containing a biphasic calcium phosphate ceramic (Triosite) for the treatment of degenerative cervical diseases.

## 2. Materials and methods

One hundred patients with degenerative cervical spondylosis undergoing anterior discectomy were enrolled in our study from January 2000 to October 2002. Inclusion into this study depended on clinical symptoms and magnetic resonance imaging (MRI) findings. Before operation, most patients received at least 3 months of conservative treatment including medicine, rehabilitation, and collar support. They were randomly divided into 2 groups. Group A (n = 50) patients underwent treatment with a PEEK cage (Stryker, Allendale, NJ) containing a biphasic calcium phosphate ceramic (Triosite, 40%  $\beta$ -tricalcium phosphate [ $\beta$ -TCP] and 60% HA, Zimmer, Berlin, Germany) for cervical interbody fusion. Group B (n = 50) patients underwent treatment with a PEEK cage containing an iliac bone autograft for fusion. The demographics of the patients are shown in Table 1. Patients with acute spinal injury or spinal infection were excluded from our study.

Anterior discectomy was performed according to the Smith-Robinson method [32]. We used a high-speed burr (Anspach, Florida) to remove the degenerative spurs to enlarge the neuroforamen. The bulging disk was removed with microforceps and curettes, and the posterior longitudinal ligament was also removed. The endplate of the vertebral body was curetted before interbody cage fusion. In group A, we cut the Triosite blocks into several segments and impacted them into the cavity of the PEEK cage (Fig. 1, left). Usually, we chose a proper size of cage (5, 6, or 7 mm




Fig. 1. A PEEK cage containing Triosite (left) and a PEEK cage containing an autograft (right).

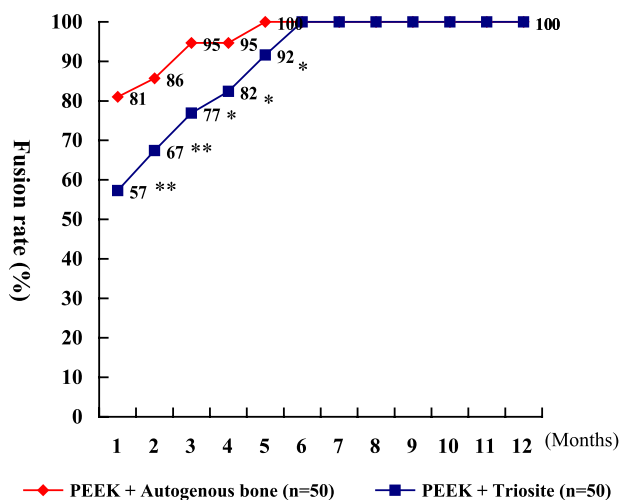


Fig. 2. The fusion rate of group A had a statistical value lower than that of group B in the postoperative first 5 months. Both groups reached complete fusion after the postoperative 6 months. Asterisk indicates  $P < .05$ ,  $\chi^2$  test; doubles asterisks,  $P < .01$ ,  $\chi^2$  test.

height) for fusion. In group B, the iliac bone marrow was extracted through a 1- to 2-cm skin incision by a T-shaped puncture needle. The extracted iliac autograft was impacted into the PEEK cavity for fusion (Fig. 1, right).

An X-ray procedure of the cervical spine including standard, flexion-extension, and bilateral oblique forms was performed postoperatively every month until the fusion was complete. Fusion was considered complete when a trabecular bone across the interfaces appeared. Nonunion was noted if the lucency between the implants and vertebral endplates surfaced. The definition of spinal fusion was

based on a previous study [10]. It is certain that a computed tomography scan is more helpful and confirmative for fusion study, but its cost is higher than an x-ray procedure. Therefore, we also used computed tomography scan and even MRI for this study when the x-ray did not ascertain results. Bone marrow ingrowth in MRI showed a high intensity in T1W1 and a low intensity in T2WI. Graft collapse was defined if the graft height loss was more than 3 mm. A straight line from the posterior border of the dens to the posterior border of C7 was drawn. Another line was drawn from the posterior border of C4 perpendicular to the first line. The intersected length was measured in millimeters and represented the degree of spinal curvature [30]. A positive intersected length indicated lordosis. If the intersected length was negative, it indicated kyphosis. If the intersected length was 0, the spinal curve was referred to as straight. The neuroforamen size of each level was measured in bilateral oblique x-ray by a computer system.

Excessive operation time, blood loss, hospital stay, and surgical complications were recorded. The neurological outcomes, both preoperatively and postoperatively, in both groups were measured according to their Japanese Orthopedic Association (JOA) score. The recovery rate (JOA) was measured by the method of Hirabayashi et al [15]. Recovery rate (%) =  $\frac{\text{postop score} - \text{preop score}}{17 (\text{full}) - \text{preop score}} \times 100$ . The follow-up period ranged from 1 to 2.5 years (mean, 1.7 years).

### 3. Results

The fusion rates in the first 6 months in group A were 57%, 67%, 77%, 82%, 92%, and 100%. The fusion rates

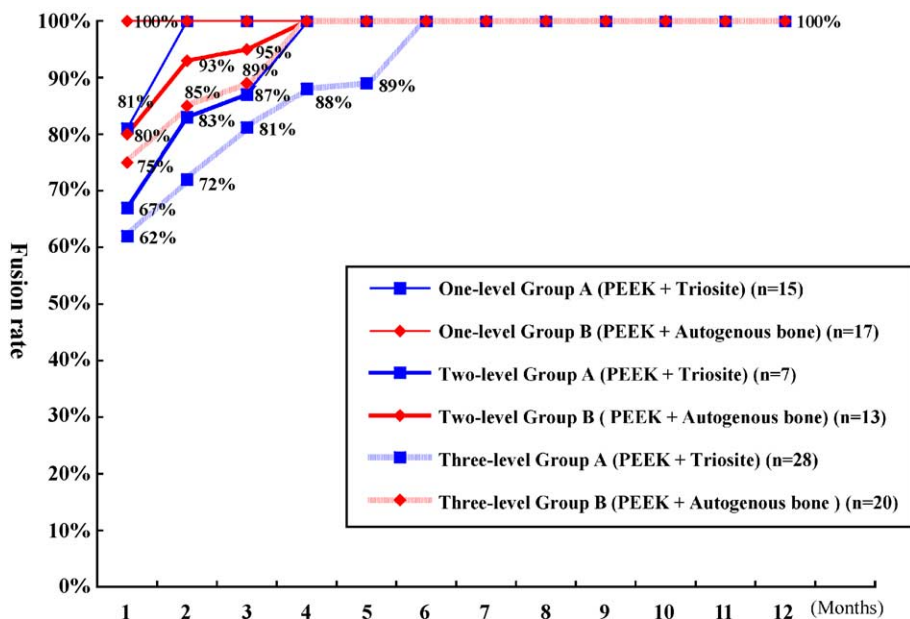


Fig. 3. There were no statistical differences between group A and group B in comparisons of one-level, two-level, and three-level fusion, respectively, Fisher exact test, 2-tail. Time to complete fusion in both groups was delayed when the fusion level increased.

within the first 6 months in group B were 81%, 86%, 95%, 95%, 100%, and 100%. Within the first 6 months, the fusion rate in group A was significantly lower than that in group B ( $P < .01$  and  $P < .05$ , respectively). However, the fusion reached 100% in both groups by the sixth month (Fig. 2). For one-level, two-level, and three-level comparisons, there were no statistical differences in both groups. Within the first 6 months, as the fusion level increased, the fusion rates reduced and the time to fusion was delayed (Fig. 3). A patient with a PEEK cage containing Triosite for spinal fusion is shown in Fig. 4.

Preoperative and postoperative spinal curvatures, neuroforamen sizes, and JOA scores in both groups are shown in Table 2. There were no statistical differences in changes of spinal curvature, neuroforamen size, and JOA recovery in both groups. Excessive blood loss and excessive operative time for iliac bone graft in group B were  $15 \pm 5$  mL and  $10 \pm 6$  minutes, as shown in Table 3. There were no donor site complications in group A but there was a 6% occurrence in group B (1, wound infection; 1, numbness of thigh; and 1, subcutaneous hematoma) ( $P < .001$ ). The hospital stay was shorter for patients in group

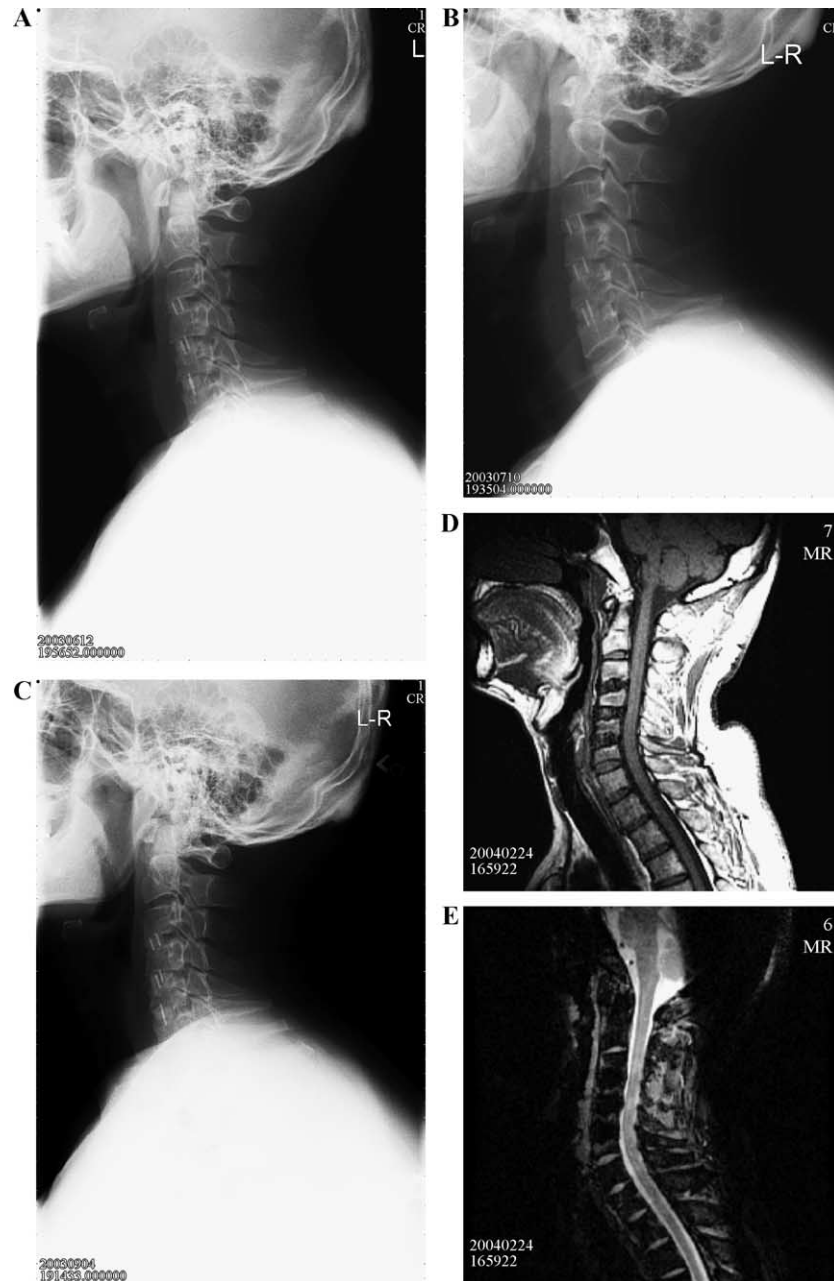


Fig. 4. A: A 45-year-old male patient with cervical spondylosis in C3-C6 at 2 months postoperative. B: Bony fusion on C3-C4 and C4-C5 at 3 months postoperative. C: Complete three-level fusion at 5 months postoperative. D: Magnetic resonance imaging T1WI showed high intensity of bone marrow in cages. E: Magnetic resonance imaging T2WI showed low intensity of bone marrow in cages.

Table 2  
Comparisons of spinal curvature, neuroforamen size, and JOA score in both groups

		Group A	Group B	P
Spinal curvature	Preop	3.13 ± 5.25	3.90 ± 4.82	.47
	Postop	5.63 ± 5.20	6.28 ± 5.02	.55
	Difference	2.07 ± 3.19	2.38 ± 3.18	.65
Neuroforamen size	Preop	45.77 ± 21.43	47.41 ± 26.69	.74
	Postop	88.78 ± 23.30	89.14 ± 31.50	.76
	Difference	43.09 ± 16.15	41.69 ± 23.74	.64
JOA score	Preop	13.54 ± 1.70	13.09 ± 2.19	.33
	Postop	16.38 ± 1.27	16.57 ± 1.73	.25
	Difference	2.84 ± 1.18	2.48 ± 0.97	.17
	Recovery rate (%)	86.51 ± 20.81	83.48 ± 26.36	.22

Preop indicates preoperative; Postop, postoperative.

P: Student *t* test.

A ( $4.43 \pm 2.36$  days) than for patients in group B ( $7.00 \pm 3.77$  days) ( $P = .001$ ).

## 4. Discussion

### 4.1. Physical characteristics of Triosite

Biphase ceramic calcium phosphate (Triosite) has 2 components, 40%  $\beta$ -TCP and 60% HA. The Triosite was prepared in a macroporous form (40%-50% macropores form 400-600  $\mu\text{m}$  in diameter) [29]. Hydroxyapatite has a low solubility, remains stable for a longer period, and undergoes chemical bonding by a formation of thin-layer apatites [8,18,19]. Hydroxyapatite is a chemical identical to inorganic bone substance that is proven to be optimally biocompatible, nontoxic, nonantigenic, and osteotropic [16]. The biointegration progress of Triosite is caused by a partial dissolution of the ceramic crystals ( $\beta$ -TCP) by multinucleated cells. Simultaneously, bone ingrowth at the expense of ceramic biologic resorption is observed [8,18,19,27,28]. In a dog experiment, the biologic resorption of Triosite decreased 1 month after implantation [8]. Hydroxyapatite acts as an osteoconductive matrix between the endplates of vertebral bodies. Calcium phosphate more easily released from tricalcium phosphate facilitates osteoclastic and osteoblastic activities [43]. The ratio of HA and  $\beta$ -TCP influences ceramic bioactivity in new bone formations [43]. In a rabbit cell culture, Yamada et al [43] reported that pure 100% HA had less solubility, less osteoclastic calcium resorption, and less osteoblastic bone formation. In our study, we used Triosite (40%  $\beta$ -TCP and 60% HA) to control the osteoclastic resorption of calcium phosphate ceramics for improving ceramic bioactivity and bony formation.

The mechanical properties of bioactive HA have a density of 3.1, a Young's modulus ( $10^2 \text{ N/mm}^2$ ) of 0.019, a compressive strength ( $10^2 \text{ N/mm}^2$ ) of 0.6, a bend strength ( $10^2 \text{ N/mm}^2$ ) of 0.12, and a hardness ( $10^2 \text{ N/mm}^2$ ) of 0.45 [8]. Initially, Triosite itself is brittle and too weak to tolerate

physiological stress but it when incorporated in PZZK cage becomes almost as strong as an active bone [17].

### 4.2. Ceramic only without cage for fusion

In a dog experiment with pure 100% of tricalcium phosphate ceramic ( $\beta$ -TCP) for cervical interbody fusion, Shima et al [34] reported that 50% of cases had graft collapse and 70% had graft anterior or posterior displacement. Cook et al [6] reported that implant fracture and extrusion into adjacent soft tissues occurred in 9 of 23 cases with HA graft materials in canine cervical spinal fusions. Without cage protection, a ceramic cannot tolerate cervical lording force [4,37,38]. However, biphasic calcium phosphate ceramic was a good substitute for autograft in the treatment of periodontal osseous defects [24,25] and for posterolateral lumbar fusion in a scoliosis operation [29,31].

### 4.3. Cages containing ceramics

Mooney et al [23] reported that total incorporation by ingrowth of a new bone could be expected in cages containing ceramics in a goat model. They confirmed that the amount of ingrowth with a fusion cage containing HA granules was about the same as that with an autogenous graft at 3 months of follow-up. Hashimoto et al [14] reported that a carbon cage filled with a mixture of local morselized bone and bioactive ceramic granules yielded solid union with satisfactory alignment and adequate disk height without need for harvest of an iliac crest graft, and a cage provide immediate rigid immobilization and share the cervical load on ceramics to prevent collapse, fracture, and displacement [1,14,26]. Therefore, in our study, the fusion rate reached 100% in both groups by the sixth month. The spinal curvature correction, neuroforamen enlargement, and JOA score recovery rate were the same in both groups.

Recently, Agrillo et al [1] demonstrated that complete fusion without evidence of breakage, collapse, pseudarthrosis, subsidence, angular deformity, or protrusion was achieved with a carbon fiber cage containing coralline (calcium carbonate) HA. This was one of the preliminary reports about an HA cage to treat cervical spinal fusion. However, most patients in this report were single-level cases (73%), and there were no patients with a three-level fusion.

Table 3  
Comparisons of excessive time, blood loss, complications of iliac grafting, and hospital stays in both groups

	Group A	Group B	P
Excessive operative time (min)	0	15 ± 5	.0001
Excessive blood loss (mL)	0	10 ± 6	.0001
Donor site complications (%)	0	6%	.0001
Hospital stay (d)	4.43 ± 2.36	7.00 ± 3.77	.002

P: Student *t* test.

As far as we know, a successful rate for multilevel fusion still had a crucial challenge because the fusion rate and surgical outcome seemed to decline as the level increased [40,41].

#### 4.4. Why the Triosite had an initially low fusion rate and delay to complete fusion?

Triosite is made of calcium phosphate exclusively not containing osteoblasts and osteocytes. It provides the only osteoconductive role in cervical fusion although some authors propose that it has bone formation stimulation. The bony ingrowth under biodegradation and ingratiation processes takes 6 to 8 months in an animal study [22]. Therefore, in our clinical study, the Triosite group had a low fusion rate in the early postoperative 5 months and took more time to achieve complete fusion. It is also reasonable to predict that the fusion time is more delayed in the Triosite group than in the autograft group. However, from spinal curvature correction, changes of neuroforamen size, and JOA score recovery, these 2 groups have no statistical differences. It seems that delayed time to fusion has no influence on clinical outcomes.

#### 4.5. Advantage of cages containing Triosite

A Triosite cage shortens hospital stay, reduces donor site complications, and decreases operative time and blood loss during iliac bone harvesting. Profeta et al [30] reported that the hospital stay was shorter for patients who underwent the procedure with the cage than for patients who had an iliac bone graft only (4 vs 8 days). In our study, the hospital stay for patients in the Triosite cage group was 4.43 days compared with 7 days for patients in the autograft group. The hospital stay was shorter for those in the Triosite group because cages containing Triosite did not result in donor site complications or donor site pain. The donor site complication rate was only 6% in group B in our study because the autografts were taken by a T-shaped aspiration handle, which resulted in a minimal amount of bone marrow extraction. St John et al [35] reported that mean operation time might be prolonged (20 minutes) and that the mean cost from iliac graft harvesting might be increased (US \$1154). Kurz et al [21] also reported that increased blood loss and operative time were found in iliac bone graft harvesting. Because of no iliac bone harvesting, the operative time and blood loss were reduced in the Triosite group.

## 5. Conclusions

Although fusion time is longer with the cage containing Triosite than with the cage containing an autograft, there was no difference in fusion rate between the 2 groups 6 months after the operation. The clinical outcome was satisfactory in both groups. The cage containing Triosite

lead to shorter hospital stay, a reduction in blood loss, and shorter operative time for iliac grafting and did not result in donor site complications. Based on our own results, the cage containing Triosite is a good substitute in treating cervical spondylotic fusion.

## Acknowledgments

This study was financially supported by a grant from the CMUH and was assisted by Ms Li Je for statistical management.

## References

- [1] Agrillo U, Mastronardi L, Puzilli F. Anterior cervical fusion with carbon fiber cage containing coralline hydroxyapatite: preliminary observations in 45 consecutive cases of soft disc herniation. *J Neurosurg (Spine 3)* 2002;96:273-6.
- [2] An HS, Simpson JM, Glover JM, Stephany J. Comparison between allograft plus demineralized bone matrix versus autograft in anterior cervical fusion: a prospective multicenter study. *Spine* 1995;20:2211-6.
- [3] Bohlman HH, Emery SE, Goodfellow DB, Jones PK, Ohio C. Robinson anterior cervical discectomy and arthrodesis for cervical radiculopathy: long-term follow-up of one hundred and twenty-two patients. *J Bone Joint Surg* 1993;75:1298-307.
- [4] Boker DK, Schultheiß R, van Roost D, Osborn JF, Kaden B. Anterior cervical discectomy and vertebral interbody fusion with hydroxylapatite ceramic: preliminary results. *Acta Neurochir (Wein)* 1993;121:191-5.
- [5] Cho DY, Liao WR, Lee WY, Liu JT, Chiu CL, Sheu PC. Preliminary experience using a polyetheretherketone (PEEK) cage in the treatment of cervical disc disease. *Neurosurgery* 2002;51:1343-50.
- [6] Cook SD, Reynolds MC, Whitecloud TS, Routman AS, Harding AF, Kay JF, Jarcho M. Evaluation of hydroxyapatite graft materials in canine cervical spine fusions. *Spine* 1986;11:305-9.
- [7] Coric D, Branch Jr CL, Jenkins JD. Revision of anterior cervical pseudarthrosis with anterior allograft fusion and plating. *J Neurosurg* 1997;86:969-74.
- [8] Daculsi G, Passuti N, Martin S, Deudon C, Legeros RZ, Rather S. Macroporous calcium phosphate ceramic for long bone surgery in humans and dogs: clinical and histological study. *J Biomed Mater Res* 1990;24:379-96.
- [9] DePalma AF, Rothman RH, Lewinnek GE, Kanale ST. Anterior interbody fusion for severe cervical disc degeneration. *Surg Gynecol Obstet* 1972;134:755-8.
- [10] Eck KR, Lenke LG, Bridwell KH, Gilula LA, Lashgari CJ, Riew KD. Radiographic assessment of anterior titanium mesh cages. *J Spinal Disord* 2000;13:501-9.
- [11] Emery SE, Fisher JRS, Bohlman HH. Three-level anterior cervical discectomy and fusion. *Spine* 1997;22:2622-5.
- [12] Ghent WR. Further studies on meralgia paresthetica. *Can Med Assoc J* 1961;85:871-5.
- [13] Grossman W, Peppelman WC, Baum JA, Krasu DR. The use of freeze-dried fibular allograft in anterior cervical fusion. *Spine* 1996;17:565-9.
- [14] Hashimoto T, Shigenobu K, Kanayaa M, Harada M, Oha F, Ohkoshi Y, Tada H, Yamamoto K, Yamane S. Clinical results of single-level posterior lumbar interbody fusion using the Brantigan I/F carbon cage filled with a mixture of local morselized bone and bioactive ceramic granules. *Spine* 2002;27:258-62.
- [15] Hirabayashi K, Miyakawa J, Satomi K, Maruyama T, Wakano K. Operative results and postoperative progression of ossification among patients with ossification of cervical posterior longitudinal ligament. *Spine* 1981;6:354-64.

- [16] Hirsch RS, Sith K, Vernon-Roberts B. A morphological study of macrophage and synovial cell interactions with hydroxyapatite crystals. *Ann Rheum Dis* 1985;44:844-51.
- [17] Holmes R, Mooney V, Bucholz R, Tencer A. A coralline hydroxyapatite bone graft substitute: preliminary report. *Clin Orthop Relat Res* 1984;188:252-62.
- [18] Jarcho M. Calcium phosphate ceramics as hard tissue prosthetics. *Clin Orthop Relat Res* 1981;157:259-78.
- [19] Jarcho M, Kay JF, Dorbeck HP, Domerus RH. Tissue, cellular and subcellular events at bone ceramic hydroxylapatite interface. *J Bioeng* 1976;1:79.
- [20] Kaiser MG, Haid Jr RW, Subach BR, Barnes B, Rodts Jr GE. Anterior cervical plating enhances arthrodesis after discectomy and fusion with cortical allograft. *Neurosurgery* 2002;50:229-38.
- [21] Kurz LT, Garfin SR, Booth Jr RE. Harvesting autogenous iliac bone grafts: a review of complications and techniques. *Spine* 1989;14:1324-31.
- [22] Metseger DS, Driskell TD, Paulsrud JR. Tricalcium phosphate ceramic: a resorbable bone implant: review and current status. *J Am Dent Assoc* 1982;105:1035-8.
- [23] Mooney V, Massie JB, Lind BI, Rah JH, Negri S, Holmes RE. Comparison of hydroxyapatite granules to autogenous bone graft in fusion cages in a goat model. *Surg Neurol* 1988;49:628-33.
- [24] Nery EB, Lynch KL. Preliminary clinical studies of bioceramic in periodontal osseous defects. *J Periodontol* 1978;49:523-7.
- [25] Nery EB, Lee KK, Czajkowski S, Dooner JJ, Dggan M, Ellinger RF, Henkin JM, Hines R, Miller M, Olson JW, Rafferty M, Sullivan T, Walters P, Welch D, Williams A. A veterans administration cooperative study of biphasic calcium phosphate ceramic in periodontal osseous defects. *J Periodontol* 1990;61:737-44.
- [26] Ohyma T, Kubo Y, Iwata H, Taki W. Beta-tricalcium phosphate as a substitute for autograft in interbody fusion cages in the canine lumbar spine. *J Neurosurg* 2002;97S:350-3.
- [27] Osborn IF, Nesly H. Bonding osteogenesis induced by calcium phosphate ceramic implants. In: Winter GD, Gibbons DF, Plen H, editors. *Biomaterials* 1980. New York: Wiley; 1982. p. 51-8.
- [28] Osborn JF, Newesely H. The materials science of calcium phosphate ceramic. *Biomaterials* 1980;1:108-11.
- [29] Passuti N, Daculsi G, Rogez JM, Martin S, Bainvel JV. Macroporous calcium phosphate ceramic performance in human spine fusion. *Clin Orthop Relat Res* 1989;248:169-76.
- [30] Profeta G, deFalco R, Ianniciello G, Profeta L, Cigliano A, Raja AI. Preliminary experience with anterior cervical microdiscectomy and interbody titanium cage fusion (Novus CT-1) in patients with cervical disc disease. *Surg Neurol* 2000;53:417-26.
- [31] Ransford AO, Morley T, Edgar MA, Webb P, Passuti N, Chopin D, Morin C, Michel F, Garin C, Pries D. Synthetic porous ceramic compared with autograft in scoliosis surgery: a prospective, randomized study of 341 patients. *J Bone Joint Surg Br* 1998;80:13-8.
- [32] Robinson R, Smith G. Anterior lateral disc removal and interbody fusion for cervical disc syndrome. *Bull Johns Hopkins Hosp* 1955;69:223-4.
- [33] Robinson R, Walker AE, Ferlic DC, Wiecking DK. The results of anterior interbody fusion of the cervical spine. *J Bone Joint Surg Am* 1962;44A:1569-87.
- [34] Shima T, Keller JT, Alvira MM, Mayfield FH, Dunsker SB. Anterior cervical discectomy and interbody fusion: an experimental study using synthetic tricalcium phosphate. *J Neurosurg* 1979;51:533-8.
- [35] St John TA, Vaccaro AR, Sah AP, Schaefer M, Berta SC, Albert T, Hillbrand A. Physical and monetary costs associated with autogenous bone graft harvesting. *Am J Orthop* 2003;32:18-23.
- [36] Summers BN, Eisenstein SM. Donor site pain from the ilium: a complication of lumbar spine fusion. *J Bone Joint Surg* 1989;71 [B]:677-80.
- [37] Thalgot JS, Fritts K, Giuffre JM, Timlin M. Anterior interbody fusion of cervical spine with coralline hydroxyapatite. *Spine* 1999;24:1295-9.
- [38] Thorell W, Cooper J, Hellbusch L, Leibrock L. Long-term clinical outcome of patients undergoing anterior cervical discectomy with and without intervertebral bone graft placement. *Neurosurgery* 1998;43:268-74.
- [39] Tomford WW, Starkweather RJ, Goldman MH, Maryland B. A study of the clinical incidence of infection in the use of banked allograft bone. *J Bone Joint Surg Am* 1981;63:244-8.
- [40] Wang JC, McDonough PW, Endow KK. Increased fusion rates with cervical plating for two-level anterior cervical discectomy and fusion. *Spine* 2000;25:41-5.
- [41] Wang JC, McDonough PW, Linda EA, Kanim MA, Endow KK, Delamarter RB. Increased fusion rates with cervical plating for three-level anterior cervical discectomy and fusion. *Spine* 2001;26:643-7.
- [42] Whitecloud III TS. Complications of anterior cervical fusion. The American Academy of Orthopaedic Surgeons. Instructional course literature. St Louis: CV Mosby Co; 1978. p. 223-7.
- [43] Yamada S, Heymann J, Boulter M, Daculsi G. Osteoclastic resorption of calcium phosphate ceramics with different hydroxyapatite/ $\beta$ -tricalcium phosphate ratios. *Biomaterials* 1997;18:1037-41.
- [44] Younger EM, Chapman MW. Morbidity at bone graft donor sites. *J Orthop Trauma* 1989;3:192-5.
- [45] Zdeblick TA, Cooke ME, Kunz DN, Wilson D, McCabe RP. Anterior cervical discectomy and fusion using a porous hydroxyapatite bone graft substitute. *Spine* 1994;19:2348-57.
- [46] Zdeblick TA, Ghanayem AJ, Rapoff AJ, Swain C, Bassett T, Cooke ME, Markel M. Cervical interbody fusion cages: an animal model with and without bone morphogenetic protein. *Spine* 1998;23:758-66.

---

## Commentary

Cho et al have provided a provocative study on the use of biphasic calcium phosphate ceramics to aid in the fusion of the anterior cervical spine. Different ceramics and non-ceramics have been used for spinal reconstruction. Hydroxyapatites and tricalcium phosphates have been studied for bone ingrowth, toxicity, and mechanical strength. The main problem has been strength vs porosity. The more porous ceramics provide for good bony ingrowth but with poor mechanical stability. The less porous admixtures are excellent for mechanical strength, notably axial compression, but are suboptimal for osseous integration.

The authors' novel technique of using a nonresorbable aryl amine (PEEK) with a ceramic is enticing. We are currently using a PEEK rectangle with a recombinant bone morphogenetic protein (rH-BMP2) in the anterior cervical spine with excellent early results. It may be that the concomitant use of a polymer with a ceramic leads to an excellent arthrodesis.

Regis William Haid Jr, MD  
*Atlanta Brain & Spine Care*  
*Atlanta, GA 30309, USA*

This paper reviews the results of using a biphasic calcium phosphate ceramic in PEEK interbody cages. When such cages were compared with PEEK cages containing an iliac crest autograph (controlled group of patients), a delay in the time to achieve successful fusion was noted. However, this